

Initial promising results of the dynamic locking blade plate, a new implant for the fixation of intracapsular hip fractures: results of a pilot study

W. H. Roerdink · A. M. M. Aalsma ·
G. Nijenbanning · A. D. P. van Walsum

Received: 24 December 2009
© Springer-Verlag 2010

Abstract

Introduction The osteosynthesis of intracapsular hip fractures results in a 19–48% failure rate. Only when the anatomical reduction is secured by stable fixation, revascularisation of the femoral head can take place and the fracture can heal by primary osteonal reconstruction. The common implants lack rotational and/or angular stability. Also the relative large volume of the implants within the femoral head compromises the (re)vascularisation. The combination of an anatomical reduction and a low volume, dynamic implant, providing angular and rotational stability seem to be crucial factors in the treatment of intracapsular hip fractures. This assumption formed the starting point for the development of the dynamic locking blade plate (DLBP), a new implant for the internal fixation of intracapsular hip fractures. This report describes the first clinical results of the new implant.

Patients and methods Internal fixation with the DLBP was performed in 25 consecutive patients with an intracapsular hip fracture within 24 h from admission. Failure of fixation, due to non-union, avascular necrosis, implant failure or secondary displacement of the fracture, was the primary outcome measurer. Functional outcome was assessed by the Harris Hip Score.

Results Following internal fixation of intracapsular hip fractures with the DLBP, a failure rate of 2 out of 25

patients and excellent functional results were seen after a follow-up of more than 2 years.

Conclusion The initial clinical results of the DLBP are promising and justify the start of a randomised controlled trial.

Keywords Femoral neck fracture · Hip fracture · Internal fixation · Bone healing · Avascular necrosis · Non-union

Introduction

Proximal femoral fractures can be classified into intracapsular and extracapsular hip fractures. Intracapsular hip fractures can be further classified into those which are displaced and those which are essentially undisplaced. Many other classification methods exist for the intracapsular hip fractures but these have not shown to be of reliable clinical usefulness [1, 3, 8, 16]. Non-operative treatment of intracapsular hip fractures is unpredictable and leads to high failure rates (46%) [15]. Intracapsular hip fractures are therefore generally managed surgically, either by internal fixation of the fracture using various implants and thereby preserving the femoral head, or by hip replacement with an endoprosthesis. Concerning the first option, three main complications may follow internal fixation: avascular necrosis, non-union and implant failure. A meta-analysis performed by Lu Yao and, more recently, Bhandari showed a reintervention rate of, respectively, 35 and up to 48% due to the complications as mentioned above after internal fixation of displaced intracapsular hip fractures [2, 7]. Studies on the internal fixation of intracapsular hip fractures that also include undisplaced fractures report better results. Parker reported an incidence of non-union of 8.5% following internal fixation of

W. H. Roerdink (✉) · A. D. P. van Walsum
Department of Traumatology, Medisch Spectrum Twente,
PO BOX 50.000, 7500 KA Enschede, The Netherlands
e-mail: roerdink.bouman@wxs.nl

A. M. M. Aalsma · G. Nijenbanning
BAAT Medical Engineering, Hengelo, The Netherlands

undisplaced intracapsular fractures versus 30.1% for displaced fractures. The overall incidence of non-union was 19.3% [9].

There are many implants available for the internal fixation of intracapsular hip fractures. However, a Cochrane review, performed by Parker and Stockton [10], concluded that none of the implants tested were found to be significantly superior for any of the outcome measures related to fracture healing complications or mortality. Parker and Stockton [10] also concluded that the sliding hip screw systems (SHS) and multiple parallel screw techniques are the only methods that have been comprehensively evaluated.

Disappointed by the results achieved with the current implants we designed and developed a new implant specifically for the internal fixation of intracapsular hip fractures. It bears the working name “dynamic locking blade plate (DLBP)” and will soon be available as the Gannet[®] (Pro-Motion Medical, Zwijndrecht, The Netherlands). In March 2009 we reported on the results of the biomechanical tests of this new implant [13]. Characteristics of the DLBP are its low implant volume, the firm fixation within the femoral head, the superior rotational stability when compared to the SHS and twin hook [13], the angular stability and its simple use. An illustration and description of the DLBP can be seen in Fig. 1.

In this report the first clinical results of the DLBP after 2 years of follow-up are demonstrated.

Surgical technique

Based on the specific type of bone healing and the specific vascularisation of the femoral head, the backbone of operative treatment of intracapsular hip fractures is an anatomical reduction and firm fixation of the femoral head allowing dynamic compression [11, 12, 14].



Fig. 1 The dynamic locking blade plate (DLBP). The implant consists of: dynamic winged locking blade including two impactation anchors, barrelled side plate (similar to the SHS), two cortical screws

After anatomical reduction of the fracture a 3.0-mm 135° guide wire is placed centrally in the femoral head followed by cannulated reaming up to 5 mm in the femoral head. Then the locking blade together with a two-hole side plate is mounted on the introducer (Fig. 2). The complete implant is introduced over the guide wire and gently tapped in while the mounted side plate functions as a rotational guide. After the side plate is seated along the lateral cortex, the introducer is released and the locking blade further tapped in the femoral head up to 5 mm subchondrally. Next the side plate is fixed with two cortical screws. By turning the set screw clockwise in the shaft of the locking blade, the impactation anchors are expanded by which the blade is locked within the femoral head (Figs. 3, 4).

Notes on the surgical technique

The aim is an anatomical reduction and not a valgus reduction to prevent vascular damage by kinking of the


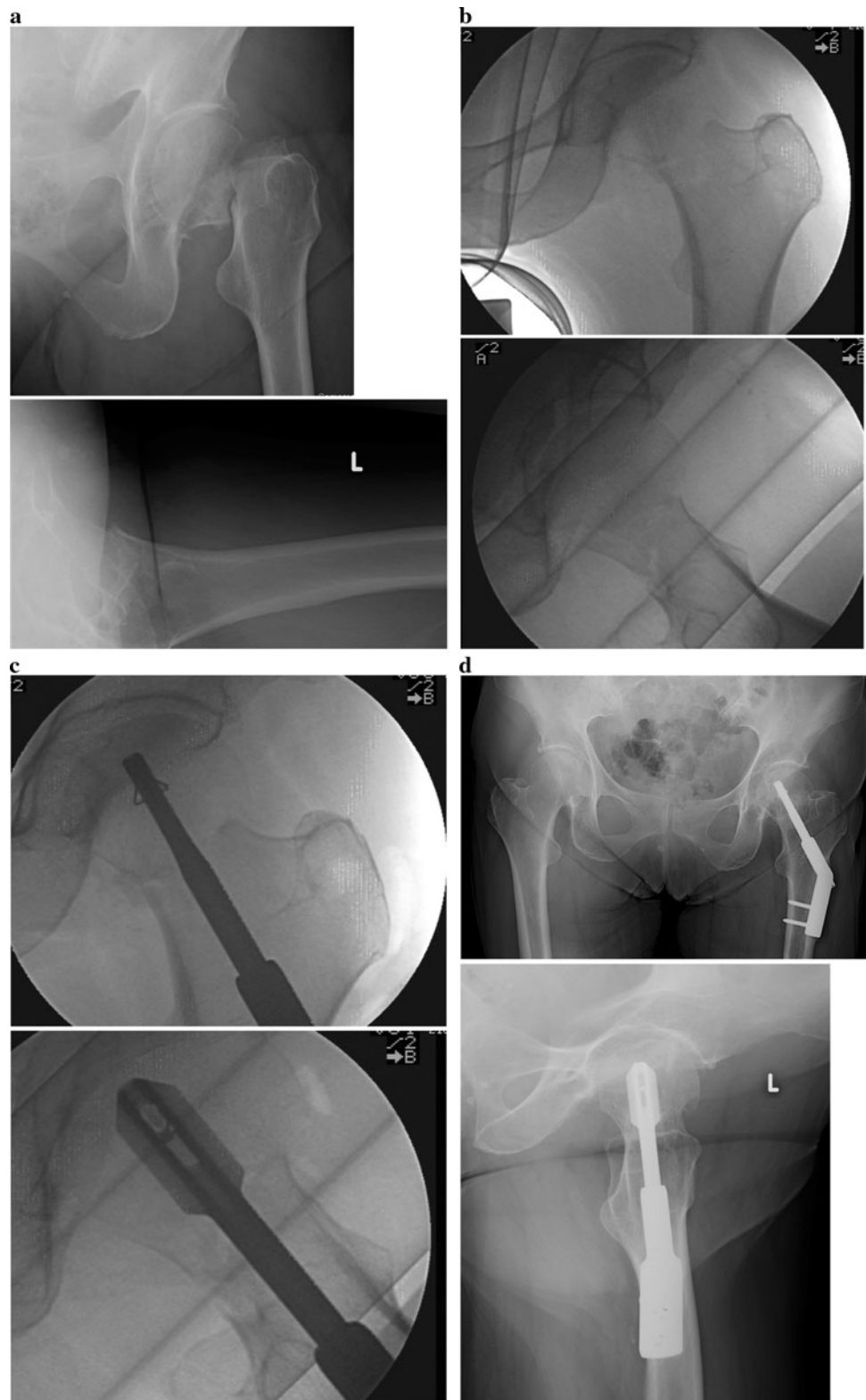


Fig. 2 Assembly of the DLBP

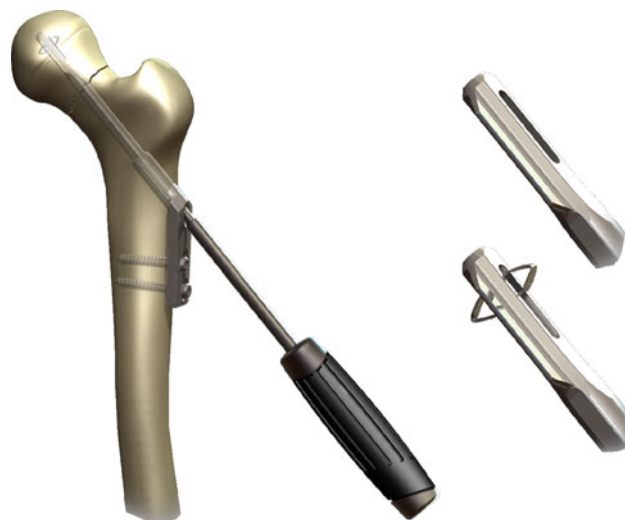

Fig. 3 Expanding the impactation anchors

Fig. 4 Radiographs of a displaced intracapsular hip fracture treated with a DLBP. **a** Preoperative radiographs of a displaced intracapsular hip fracture and **b** after reduction of the fracture. **c** The DLBP is inserted and the impaction anchors are expanded. **d** One year postoperative the fracture has healed with slight shortening of the femoral neck



lateral retinacular vessels. The guide wire is placed centrally in the femoral head because this is the rotational neutral point and in this position the risk of avascular necrosis is further reduced. Unlike the introduction of

sliding hip screw devices, no torque force at all is exerted on the femoral head. Rotational stability is provided by the side-winged tip of the locking blade and is further improved by the two impaction anchors [13]. Neither a

per-operative antirotational pin nor an extra antirotational screw is necessary. Also, no pre-tapping for the locking blade is needed. The inner diameter of the pre-drilling in the femoral head relative to the outer diameter of the shaft of the locking blade is such that no disimpaction of the fracture will occur, thereby avoiding strain on the remaining intact capsular vessels, when inserting the implant in the femoral head. The cutting time is reduced by inserting the mounted blade and plate as one single unit. The barrelled side plate provides angular stability combined with dynamic axial compression of the fracture. The impaction anchors lock the blade in the femoral head and prevent perforation and backing out of the implant. Furthermore, dynamic testing showed augmented rotational stability by the impaction anchors when compared to the SHS and Twin hook [13]. The holding power of the expanded anchors is improved by impaction of the cancellous bone. On removal, the impaction anchors are pulled in by turning the setscrew anticlockwise. During the biomechanical tests the impaction anchors never failed to withdraw [13]. After removal of the cortical screws the locking blade together with the side plate is tapped out by means of an extractor mounted on the locking blade.

Patients and methods

Based on the international orthopaedic literature it seems reasonable to set the failure rate of the common implants on 35%. Assuming a failure rate of 12%, a sample size of 26 would be needed to achieve a power of 80%. The target significance level is 5%. Based on this power assessment and the fact that it concerned a new implant, the Medical Ethics Committee allowed the inclusion of 25 patients for the first clinical DLBP trial. After getting approval we conducted a prospective, nonrandomised, monocentre, observational pilot study on the clinical results of a cohort of consecutive patients with an intracapsular hip fracture treated by internal fixation with a DLBP at our institute. Included were patients from 18 to 75 years of age with an undisplaced or displaced intracapsular hip fracture (Comprehensive Classification of Fractures type 31-B), Garden I–IV. The patients should be able to give informed consent and were mobilised without aids before trauma. Excluded were patients who suffered a hip fracture more than 12 h before admission, patients with former operations on the same hip, patients with other fractures of the lower extremities and patients with symptomatic disease of the same hip or patients unable to attend the follow-up. The procedures were performed within 24 h from admission [4]. Two surgeons participated in the trial and performed the surgical procedures. The standardized follow-up, including functional and radiological examination, was

performed at 6 weeks, 3, 6, 12 and 24 months. The mean follow-up by now is more than 2 years. The primary outcome measurer was failure of fixation due to avascular necrosis, non-union, implant failure, secondary displacement of the fracture or migration of the implant. Secondary outcome measurers of the study were the mean operation time, per- and post-operative complications, the moment of full weight bearing, and the functional outcome by the Harris Hip Score [5].

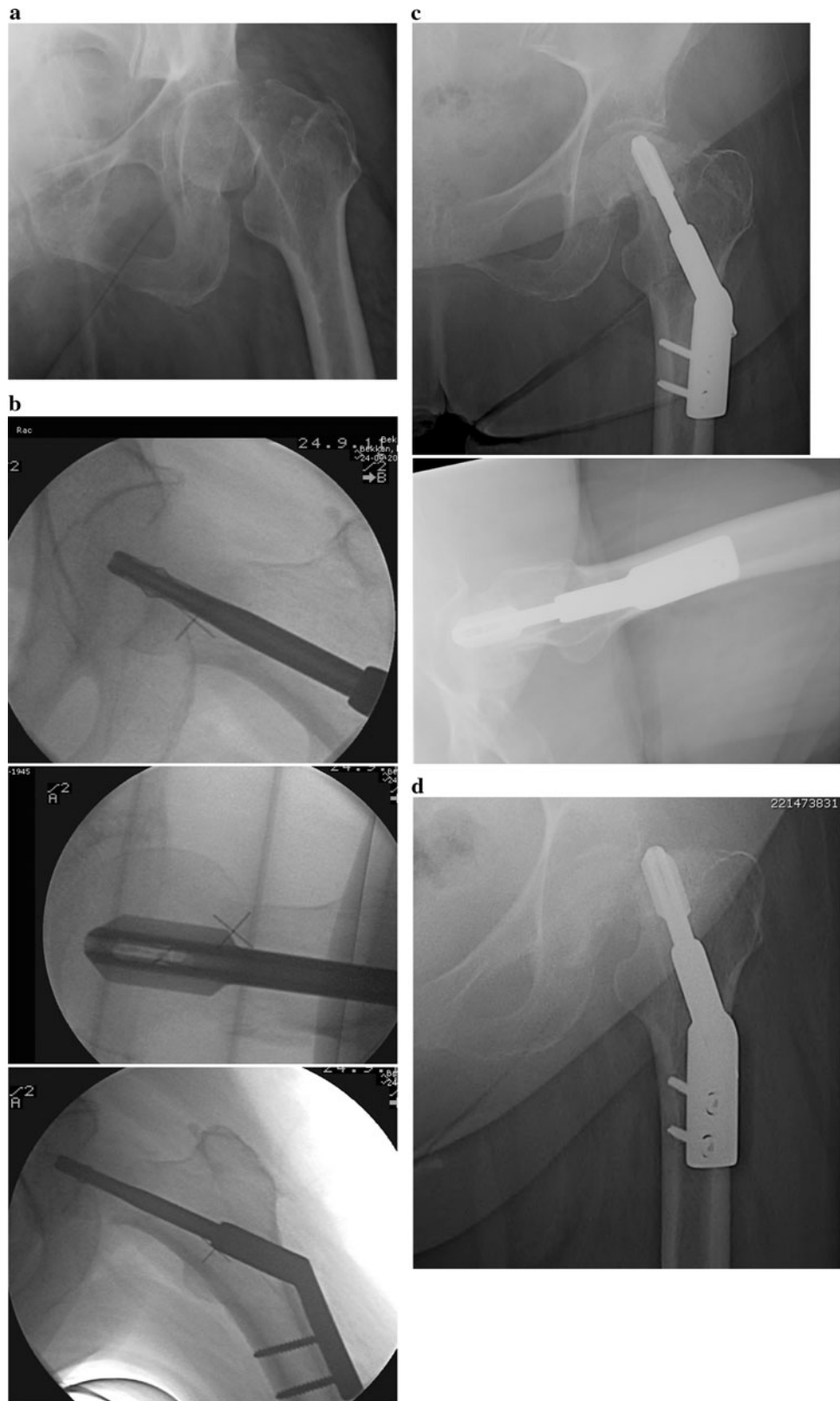
Results

From February 2006 till July 2007 51 patients younger than 76 years of age with an intracapsular hip fracture presented at our institute. Thirteen of these patients suffered from pre-existent symptomatic disease of the hip and were treated with an endoprosthesis. Another 13 patients were treated with an alternative form of internal fixation (SHS or Twin hook) because of the lack of informed consent or because the participating surgeons were not available. 25 patients (14 women, 11 men) with an intracapsular hip fracture were treated with the DLBP. The mean age of these patients was 60 years (range 39–75). Eight fractures were undisplaced (6 Garden I, 2 Garden II) and 17 were displaced (14 Garden III, 3 Garden IV). There were no per- or post-operative complications. The mean operation time, including positioning of the patient and reposition of the fracture, was 40 min, decreasing from 53 min (range 45–75) in the first 5 patients to an average of 26 min (range 20–30) in the last 5 patients. The difference in mean operation time between the first 5 patients and the last 5 patients is statistically significant ($P = 0.008$) using a Wilcoxon rank sum test. The average time to full weight bearing was 6 weeks post trauma.

After a follow-up of 2 years, in 23 out of 25 patients the bone healing was uncomplicated. One patient (ASA3, Garden IV) developed an avascular necrosis and collapse of the femoral head treated by a hemiarthroplasty (Fig. 5). In another patient (ASA2, Garden III) a non-union was diagnosed more than half a year postoperatively and this patient was treated by a total hip arthroplasty. The failure rate of 2/25 (8%) was compared with an a priori estimated failure rate from the literature of 35% with a binomial test. The difference was significant (1-sided P value 0.002). When comparing the failure rate of only the displaced hip fractures 2/17 (12%) the difference remains significant ($P = 0.033$).

Two male patients with a nearly anatomical reduction on the radiographs after 6 months and an excellent result according to the Harris Hip Score were lost to follow-up after 6 months. During the 2-year follow-up 2 patients died of unrelated causes. No secondary displacement was noted.

Fig. 5 Avascular necrosis and collapse of the femoral head. **a** Preoperative radiograph of a displaced intracapsular hip fracture. **b** Fracture reduction and internal fixation with a DLBP. **c** Three months postoperative: segmental collapse of the femoral head; the patient is eligible for hip replacement surgery. **d** Three weeks later the patient presents at the emergency department with a total collapse of the femoral head



Migration of the DLBP, determined by measuring the tip-apex distance corrected for magnification in both frontal and lateral views, was not noted. The functional outcome

showed an average Harris Hip Score after 1 year follow-up of 92 (range 76–100) and after 2 years follow-up 93 (range 73–100).

Discussion

The results of internal fixation of intracapsular hip fractures with the DLBP or Gannet[®] are, at least, promising. Internal fixation of intracapsular hip fractures with the DLBP resulted in a reintervention rate of 2 out of 25 (8%) patients, compared to a 19%–48% reintervention rate for the SHS and the multiple screws/pins fixation reported in the literature [2, 6, 7, 9]. When we only consider the displaced hip fractures, the result, 2 failures out of 17 displaced hip fractures (12%) would still mean a substantial improvement compared to the literature reporting on only displaced hip fractures [2, 7].

The patient that developed an avascular necrosis suffered from a disabling chronic obstructive pulmonary disease (COPD), obesity and a nicotine addiction which made it very likely for this patient to develop an avascular necrosis. Thus, when considering the preoperative morbidity of this patient, and although the patient was mobilised without aids before sustaining an intracapsular hip fracture, this patient should not have been treated by internal fixation. The patient that developed a non-union suffered from a stroke 1 week after surgery due to an aneurysm of the cerebral medial artery with a partial paralysis as a consequence. It is well established that the chance of developing a non-union increases with age and preoperative morbidity [9]. Under these circumstances and for the same reasons as mentioned above, this patient would also not have been treated by internal fixation.

Nevertheless, 2 failures out of 25 patients after a follow-up of 2 years remains an excellent result when compared to the international literature. This study, however, has its limitations. As the patient group is small, the study design nonrandomised, and one of the co-developers of the DLBP is involved in this study, a certain bias should be anticipated. However, the difference in outcome of this study as compared to the results mentioned in the international literature is such that it cannot be explained by bias alone and it seems likely that some implant-related effects of the DLBP are responsible. The combination of an anatomical reduction and a low volume, dynamic implant fixed within the femoral head providing angular and rotational stability are crucial factors in the treatment of intracapsular hip fractures.

Conclusion

The initial clinical results of the DLBP in the internal fixation of undisplaced and displaced intracapsular hip fractures are promising. The very low reintervention rate after a follow-up of 2 years justifies the start of a prospective, randomised multicentre trial.

Acknowledgments The authors wish to thank Joost Klaase, MD, PhD and Job van der Palen, PhD, for critically reviewing the manuscript.

Conflict of interest The authors declare that they have no financial relationships other than their mentioned affiliations.

References

1. Barnes R, Brown JT, Garden RS, Nicoll EA (1976) Subcapital fractures of the femur. A prospective review. *J Bone Jt Surg Br* 58:2–24
2. Bhandari M, Devereaux PJ, Swionkowski MF, Tornetta P III, Obremskey W, Koval KJ, Nork S, Sprague S, Schemitsch EH, Guyatt GH (2003) Internal fixation compared with arthroplasty for displaced fractures of the femoral neck. A meta-analysis. *J Bone Jt Surg Am* 85-A:1673–1681
3. Blundell CM, Parker MJ, Pryor GA, Hopkinson-Woolley J, Bhonsle SS (1998) Assessment of the AO classification of intracapsular fractures of the proximal femur. *J Bone Jt Surg Br* 80:679–683
4. Gdalevich M, Cohen D, Yosef D, Tauber C (2004) Morbidity and mortality after hip fracture: the impact of operative delay. *Arch Orthop Trauma Surg* 124:334–340
5. Harris WH (1969) Traumatic arthritis of the hip after dislocation and acetabular fractures: treatment by mold arthroplasty. An end-result study using a new method of result evaluation. *J Bone Jt Surg Am* 51:737–755
6. Krastman P, van den Bent RP, Krijnen P, Schipper IB (2006) Two cannulated hip screws for femoral neck fractures: treatment of choice or asking for trouble? *Arch Orthop Trauma Surg* 126:297–303
7. Lu-Yao GL, Keller RB, Littenberg B, Wennberg JE (1994) Outcomes after displaced fractures of the femoral neck. A meta-analysis of one hundred and six published reports. *J Bone Jt Surg Am* 76:15–25
8. Parker MJ, Dynan Y (1998) Is Pauwels classification still valid? *Injury* 29:521–523
9. Parker MJ, Raghavan R, Gurusamy K (2007) Incidence of fracture-healing complications after femoral neck fractures. *Clin Orthop Relat Res* 458:175–179
10. Parker MJ, Stockton G (2001) Internal fixation implants for intracapsular proximal femoral fractures in adults. *Cochrane Database Syst Rev* CD001467
11. Perren SM, Cordey J (1980) The concept of interfragmentary strain. In: Uthoff HK (ed) *Current concepts of internal fixation of fractures*. Springer, Berlin, pp 63–77
12. Rockwood CA Jr, Green DP, Bucholz RW, Heckman JD (1996) *Fractures in adults*. Lippincott, Philadelphia
13. Roerdink WH, Aalsma AM, Nijenbanning G, van Walsum AD (2009) The dynamic locking blade plate, a new implant for intracapsular hip fractures: biomechanical comparison with the sliding hip screw and Twin Hook. *Injury* 40:283–287
14. Sevvit S (1964) Avascular necrosis and revascularisation of the femoral head after intracapsular fractures; a combined arteriographic and histological necropsy study. *J Bone Jt Surg Br* 46:270–296
15. Verheyen CC, Smulders TC, van Walsum AD (2005) High secondary displacement rate in the conservative treatment of impacted femoral neck fractures in 105 patients. *Arch Orthop Trauma Surg* 125:166–168
16. Zlowodzki M, Bhandari M, Keel M, Hanson BP, Schemitsch E (2005) Perception of Garden's classification for femoral neck fractures: an international survey of 298 orthopaedic trauma surgeons. *Arch Orthop Trauma Surg* 125:503–505